

# Quantitative Assessment of Right Atrial Function by Strain Imaging in Adult Patients with Totally Corrected Tetralogy of Fallot

Nasim Naderi<sup>1</sup>, Zahra Ojaghi Haghighi<sup>2,\*</sup>, Sepideh Pezeshki<sup>1</sup>, Azin Alizadehasl<sup>2</sup>

<sup>1</sup> Rajaie Cardiovascular Medical and Research Center, Iran University of Medical Sciences, Tehran, IR Iran

<sup>2</sup> Echocardiography Research Center, Rajaie Cardiovascular Medical and Research Center, Iran University of Medical Sciences, Tehran, IR Iran

\*Corresponding author: Zahra Ojaghi Haghighi, MD, FACC, Echocardiography Research Center, Rajaie Cardiovascular Medical and Research Center, Iran University of Medical Sciences, Tehran, IR Iran. Tel: +98-2123922134, Fax: +98-2122055594, E-mail: zohamahsa@yahoo.com.

Received: May 11, 2013; Accepted: May 30, 2013

**Background:** Atrial function could be affected by many cardiac disorders. Recently Strain imaging has been employed for the assessment of atrial function in several disorders involving atria.

**Objectives:** We aimed to measure the right atrial function by this method in adult patients with surgically corrected Tetralogy of Fallot (TOF).

**Patients and Method:** Forty six adult patients with TOF who underwent total correction surgery in childhood and had severe pulmonary regurgitation and fulfilled the criteria of ACC/AHA guideline for PVR enrolled. The control group included 50 healthy adults with matched age and sex. Standard transthoracic echocardiography was performed on both groups which myocardial velocities and strain imaging indices were obtained from their RA free wall.

**Results:** The myocardial velocities and deformational indices of RA free wall were significantly compromised in TOF patients compared with normal subjects. There was no correlation between RA function data measured by strain imaging and RV volume measured in CMR.

**Conclusions:** In light of our findings, we concluded that RA function is severely diminished in adult patients with TOF. It would play an important role in pathophysiological process of the right sided heart failure in these patients.

**Keywords:** Right Atrial Function; Strain Imaging; Tetralogy of Fallot

## 1. Background

Atrial function could be affected in many cardiac disorders. The three components of the atrial function are: 1) the reservoir function, storing blood when the tricuspid valve is closed and releasing stored blood when it opens; 2) the conduit function, transferring passive blood directly from the coronary and systemic veins to the RV when the tricuspid valve is open; and 3) the booster pump function, contracting the atrium in late diastole to complete ventricular filling (1-10). One of the modalities to evaluate atrial function is strain imaging. According to the previous studies on the deformational properties of the left atrium (LA) (2, 6, 10) and the right atrial function (RA) (1, 3, 5, 7, 8), the systolic strain and strain rates represent the atrial reservoir function and the early and late diastolic strain rates show the conduit and booster functions, respectively. Previous studies have reported that pathologi-

cally altered atrial function can profoundly affect the cardiac performance.

## 2. Objectives

We aimed to measure the regional longitudinal strain and strain rate profiles in the right atrial wall to quantify the right atrial function in patients with totally corrected tetralogy of Fallot (TOF).

## 3. Patients and Method

### 3.1. Patient Selection

Forty-six adult patients with a diagnosis of TOF who underwent total correction surgery in childhood and had severe pulmonary regurgitation (PR) and fulfilled the criteria of American college of cardiology/American heart

### Implication for health policy/practice/research/medical education:

Our study, entitled "Quantitative assessment of right atrial function by strain imaging in patients with totally corrected tetralogy of Fallot", deals with the feasibility of measuring the regional longitudinal strain/strain rate profiles in the right atrium wall to quantify right atrium functions in patients with Tetralogy of Fallot (TOF). This study concentrated on the analysis of the right atrium deformation properties in patients with TOF and demonstrated a diminished right atrium function in this group of patients.

Copyright © 2013, Iran University of Medical Sciences. This is an Open Access article distributed under the terms of the Creative Commons Attribution License (<http://creativecommons.org/licenses/by/3.0>), which permits unrestricted use, distribution, and reproduction in any medium, provided the original work is properly cited.

association (ACC/AHA) guideline for pulmonary valve replacement (PVR) (11-13) enrolled. All of the patients were assessed by cardiac magnetic resonance (CMR) regarding their pulmonary regurgitation severity and right and left ventricular size and function. The control group was comprised of 50 healthy volunteer adults with matched

age and sex. The normal subjects were chosen by taking into account history, physical examination, ECG, and echocardiography. The study was approved by the ethics committee of Rajaie Cardiovascular, Medical and Research Center, and informed consent was obtained from all the patients.

**Table 1.** General Characteristics of the Studied Sample

General Characteristics	TOF <sup>a</sup> Patients (n = 46)	Normal Subjects (n = 50)	P value
Age, y <sup>b</sup>	25.2 ± 5.7	29 ± 14	> 0.05
Sex, No. (%)	33/13	40/35	
Male	33 (71.7)	35 (70)	
Female	13 (28.3)	15 (30)	
BSA <sup>a</sup> , m <sup>2</sup>	1.67 ± 0.12	1.78 ± 0.65	> 0.05
Systolic BP <sup>a</sup>	107.5 ± 20	120.0 ± 10.7	> 0.05
Diastolic BP,	68 ± 10	77.3 ± 5.2	> 0.05
Heart Rate,	84 ± 12	67 ± 14	> 0.05
LVEF <sup>a</sup> ,	55.9 ± 2	60 ± 5	> 0.05
RA area Index, cm/m <sup>2</sup>	17.5 ± 3.8	6.6 ± 1.3	< 0.001
RV Sm, cm/s,	9.1 ± 1.6	13 ± 1.7	< 0.001
IVC <sup>a</sup> size, mm	22 ± 3.4	10 ± 2	< 0.001
RVEDD <sup>a</sup> , mm	48 ± 1	26.5 ± 3.9	< 0.001
TAPSE <sup>a</sup> , mm	17 ± 3	25 ± 3	< 0.001
RV <sup>a</sup> diastolic volume index in CMR <sup>a</sup> , ml/m <sup>2</sup>	159 ± 8.5	—	

<sup>a</sup> Abbreviations: BP, blood pressure; BSA, body surface area; CMR, cardiac magnetic resonance; IVC, inferior vena cava; LVEF, left ventricular ejection fraction; RA, right atrium; RV, right ventricle; RVEDD, right ventricular end diastolic diameter; TAPSE, tricuspid annular plane systolic excursion; TOF, tetralogy of fallot.

<sup>b</sup> All the data are shown with Mean ± SD

### 3.2. Echocardiographic Study

A complete two-dimensional (2D) color Doppler echocardiogram was performed in each subject using a commercial GE Vivid 7 with a 3-MS variable frequency harmonic phased array transducer. The LV global systolic function was evaluated in terms of the EF, employing the biplane Simpson method. The RV systolic function was evaluated in accordance with the American Society of Echocardiography guidelines for the echocardiographic assessment of the right heart in adults (14) using the following parameters: Tricuspid annular plane systolic excursion (TAPSE) and tissue Doppler-derived tricuspid lateral annular systolic velocity (RVSm). TAPSE < 16 mm, and RVSm velocity < 10 cm/s indicated RV systolic dysfunction. The RA area was measured at the end-systole in the four-chamber view.

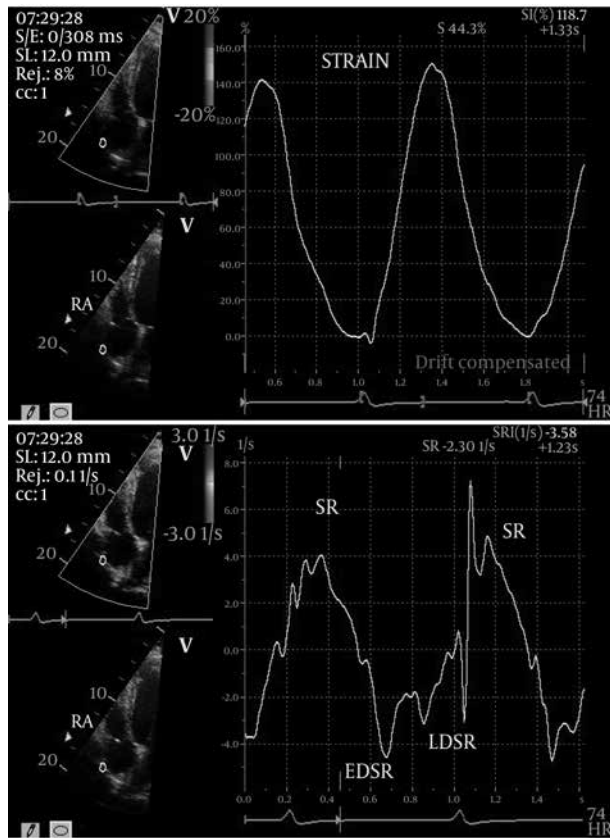
### 3.3. Strain Rate Imaging in the Right Atrium

Real-time 2-D color Doppler myocardial imaging data were recorded from the RA, using standard four chamber apical views at a high frame rate (> 150 FPS) and the narrowest sector angle possible. The data obtained were

stored in digital format and analyzed offline with dedicated software (Echopac Vivid 7). The method used for acquiring and analyzing the strain imaging of RA was based on our previous report (7). The region of interest for acquiring strain analysis was the right atrial lateral wall between 6 o'clock and 9 o'clock. The region of interest was kept at the center of the ultrasound sector to ensure the accuracy of the insonation angle with the long-axis motion. A sample volume of 3-4 mm was utilized for the calculation of the longitudinal strain rate. During the RV systole, the RA acts as a reservoir and collects blood from the caval veins while the tricuspid valve is closed; this process results in the enlargement of the RA. Also during the RV systole, the passive stretching of the RA walls leads to the longitudinal lengthening of the RA, which is recorded as a positive S and SR value. During early diastole, the RA acts as a conduit for passive emptying and as a booster pump during atrial contraction in late diastole. And finally during RV diastole, the atrial shortening occurs which is recorded as a negative SR value. This method made the calculation of the parameters of peak systolic strain (S), peak systolic strain rate (SR), early diastolic strain rate (EDSR), and late diastolic strain

rate (LDSR) possible (Figure 1). Three consecutive beats in each view were analyzed and averaged.

**Figure 1.** Right Atrial Strain Rate Analysis



Abbreviations: EDSR, early diastolic strain rate; LDSR, late diastolic strain rate; SR, strain rate

### 3.4. Statistical Analysis

All the analyses were conducted using IBM SPSS statistic 19 (IBM corp.Armonk, NY) to compare the strain imaging data the patients and normal subjects. All data were initially analyzed using the Kolmogorov-Smirnov test to assess the normality. Categorical variables are presented as numbers and percentages and quantitative variables as mean  $\pm$  standard deviation (SD). The Student's t-test was performed comparison of interval variables between two sub-groups. The Pearson's product-moment correlation coefficient was utilized to find the correlations between interval data. A P-value of 0.05 was considered statistically significant. Inter-observer variability and intra-observer variability were calculated as the absolute difference divided by the average of the two observations for all the parameters. Ten cases were analyzed for the calculation of the inter- and intra-observer variability.

### 4. Results

Among the 46 TOF patients, the mean of age  $25.2 \pm 5.7$ , 33 (71.7%) were male and 13 (28.3%) were female. All the patients were symptomatic [New York Heart Association (NYHA) class III] and had remarkable exercise intolerance assessed by standard exercise tests and severe pulmonary regurgitation based on the CMR and echocardiography criteria. Table 1 depicts general characteristics, echocardiography and CMR data of patients versus normal subjects.

The RA tissue velocities and deformational indices were severely compromised in patients compared with normal subjects (Table 2).

**Table 2.** Right Atrial Myocardial Velocities and Deformation Indices in TOF versus Normal Subjects

Velocities and Deformation Indices	TOF Patients (n = 46)	Normal Subjects (n = 50)	P value
Systolic Velocity, cm/s <sup>b</sup>	4.5 $\pm$ 1.3	9.2 $\pm$ 1.6	<0.001
Early diastolic velocity, cm/sec	3.9 $\pm$ 1.6	9.5 $\pm$ 1.8	<0.001
Late diastolic velocity, cm/sec	2.7 $\pm$ 1.2	8.3 $\pm$ 2.1	<0.001
RAS <sup>a</sup>	73.4 $\pm$ 32	132 $\pm$ 51	<0.001
RASR <sup>a</sup> , 1/s	2.7 $\pm$ 1.1	6.3 $\pm$ 3.0	<0.001
RAEDSR <sup>a</sup> , 1/s	2.7 $\pm$ 1.5	5.4 $\pm$ 1.7	<0.001
RALDSR <sup>a</sup> , 1/s	3 $\pm$ 1.5	4.5 $\pm$ 2.2	<0.001

<sup>a</sup> Abbreviations: RAEDSR, right atrial early diastolic strain rate; RALDSR, right atrial late diastolic strain rate; RAS, right atrial strain; RASR, right atrial strain rate

<sup>b</sup> All the data are shown with Mean  $\pm$  SD

As has shown in Table 2, peak RA systolic strain, indices of atrial reservoir function (SR) were severely diminished in TOF patient versus normal subjects [73.4  $\pm$  32 versus 132  $\pm$  51 ( $P < 0.001$ ) and 2.7  $\pm$  1.1 versus 6.3  $\pm$

3.0 ( $P < 0.001$ )]. EDSR and LDSR (indices of conduit and booster function of atrium) were also significantly compromised in TOF patients versus normal subjects [2.7  $\pm$  1.5 versus 5.4  $\pm$  1.7 ( $P < 0.001$ ) for EDSR and 3  $\pm$  1.5 versus

$4.5 \pm 2.2$  ( $P < 0.001$ ) for LDSR]. There was no correlation between RA deformational indices and other echocardiographic data including RV (right ventricle) size, TAPSE, RVSm, RV fractional area change and RA area. ( $r = 0.05-0.2$  with no significant  $p$  values). The mean of RV diastolic volume index was  $159 \pm 8.5$  milliliter/ $m^2$ . We also found no correlation between this CMR index -as the most important CMR variable in the assessment of TOF patients with severe PR- and the decision making for PVR, and RA deformational indices ( $r = 0.1-0.2$  with no significant  $p$  values). The intra-observer variability for the peak RA systolic strain, SR, EDSR, and LDSR was  $12.4 \pm 10\%$ ,  $12.1 \pm 11\%$ ,  $13.2 \pm 8\%$ , and  $10.8 \pm 5\%$ , respectively; and the inter-observer variability for the peak RA systolic strain, SR, EDSR, and LDSR was  $13.2 \pm 3\%$ ,  $14.2 \pm 9\%$ ,  $12.3 \pm 10\%$ , and  $11.4 \pm 7\%$ , respectively.

Strain Rate Imaging of right atrium in a normal subject. The sample volume (3-4mm) was placed in the right atrial lateral wall at an apical four-chamber view.

## 5. Discussion

The present study assessed the RA function using myocardial deformation properties in severely symptomatic TOF patients who had severe pulmonary regurgitation and were candidate for PVR. Our findings demonstrate a significant decrease in the deformational indices of the RA in TOF patients compared with the normal subjects. Recently, the utility of atrial performance for estimating cardiovascular risks, guiding therapy and decision making in various clinical settings becomes increasingly clear. Assessment of atrial size, anatomy and function can be performed with different imaging techniques (1-10). Quantification of atrial myocardial function by strain imaging has been recently proposed. The importance of right atrial function has prompted many investigators to focus on it via SRI in patients with different types of cardiovascular disorders (4, 5, 7). The strain rate imaging allows the non-invasive functional quantification of the right atrial function analyzing the deformation properties independent of cardiac rotational motion and the tethering effect. The previous studies on the deformational properties of the LA and the RA function state that the systolic strain and strain rate represent the atrium reservoir function and the early and late diastolic strain rates demonstrate the conduit and booster functions, respectively (3, 5, 8). The reduction in the RA strain and strain rate indices in our patients signifies that all three components of RA function have severely compromised. This severe RA dysfunction could be secondary to longstanding hemodynamic loads or the direct involvement of the atrial myocardial fibers by the pathologic changes related to the congenital heart disease process. Right ventricular volume overload, due to pulmonary regurgitation and/or tricuspid regurgita-

tion in TOF patients will elevate right atrial pressure and volume (11, 12). Moreover, these patients have all had intra cardiac surgery with the use of cardiopulmonary bypass and a right atrial scar, the sequel of the atriotomy necessary for the cannulation or visualization of intra cardiac structures. This scarring would lead to the loss of atrial compliance and compromise of atrial reservoir function. So, either due to the elevated right ventricular pressure or as a result of increased right ventricular volume, the right atrial wall is often stretched in patients with corrected TOF. These all together will not only lead to a compromised atrial function, but also to a high prevalence of atrial arrhythmias (7). Hui W et al. (15) study showed that tissue Doppler derived strain rate can provide quantitative analysis of the regional right atrial performance in patients with TOF. They assessed 50 asymptomatic patients following corrective surgery of tetralogy of Fallot, and concluded a significantly reduced right atrial active fractional area of emptying, along with a reduced peak strain rate. Despite severe RA dysfunction, we found no correlation between deformational indices and other echocardiographic parameters and/or RV diastolic volume index in CMR. Considering this finding accompanied with the result of Hui W et al. (15) study, it could be concluded that RA dysfunction is present in all TOF patients at early stages even in asymptomatic ones and would not be a useful index for determining the time for PVR in symptomatic patients with TOF. The long-term prognosis of adult patients with congenital heart disease is insufficiently known and largely dependent on the right-sided cardiac function (7). RA strain imaging properties could be considered as a non-invasive and comprehensive tool to assess the right side chambers function in patients with congenital heart disease including TOF. Patients with higher atrial strain imaging values seem to have a better right atrial performance. The prognostic significance of RA dysfunction and changes in RA function indices measured by SRI following PVR should be addressed in further studies.

### 5.1. Study Limitations

Similar to other Doppler modalities, tissue Doppler-derived strain measurements are dependent on the direction of the Doppler angle. Therefore, interpretation of the SR should be performed cautiously if tissue direction deviates more than  $30^\circ$  from the direction of the ultrasonic beam. In light of our findings, we concluded that RA function is severely diminished in adult patients with TOF. It could play an important role in pathophysiology of the right sided heart failure in this group of patients and should be addressed in further studies. Strain Rate Imaging of right atrium in a normal subject. The sample volume (3-4mm) was placed in the right atrial lateral wall at an apical four-chamber view.

## Acknowledgements

We would like to thank our colleagues in Rajaei Cardiovascular medical and research center in particular department of echocardiography.

## Authors' Contribution:

1) Zahra Ojaghi Haghighi, MD, FACC Associate Professor of Cardiology Fellowship in Echocardiography Designing the study, interpreting the data, and revising the manuscript, 2) Nasim Naderi, MD Assistant Professor of Cardiology Fellowship in Heart Failure and Transplantation Concept and design of the study; data collection, analysis, and interpretation; and drafting of the manuscript, 3) Sepideh Pezeshki, MD Cardiologist Fellowship in Adult congenital heart disease Data collection, analysis, and interpretation, as well as drafting of the manuscript, 4) Azin Alizadehasl, MD Assistant Professor of Cardiology Fellowship in echocardiography Data collection, analysis, and interpretation.

## Financial Disclosure:

There is no financial Disclosure.

## Funding Support:

There is no funding support.

## References

- Baur LH. Right atrial function: still underestimated in clinical cardiology. *Int J Cardiovasc Imaging*. 2008;**24**(7):711-2.
- Cameli M, Caputo M, Mondillo S, Ballo P, Palmerini E, Lisi M, et al. Feasibility and reference values of left atrial longitudinal strain imaging by two-dimensional speckle tracking. *Cardiovasc Ultrasound*. 2009;**7**:6.
- Caso P, Ancona R, Di Salvo G, Comenale Pinto S, Macrino M, Di Palma V, et al. Atrial reservoir function by strain rate imaging in asymptomatic mitral stenosis: prognostic value at 3 year follow-up. *Eur J Echocardiogr*. 2009;**10**(6):753-9.
- Cioffi G, de Simone G, Mureddu G, Tarantini L, Stefanelli C. Right atrial size and function in patients with pulmonary hypertension associated with disorders of respiratory system or hypoxemia. *Eur J Echocardiogr*. 2007;**8**(5):322-31.
- Gaynor SL, Maniar HS, Prasad SM, Steendijk P, Moon MR. Reservoir and conduit function of right atrium: impact on right ventricular filling and cardiac output. *Am J Physiol Heart Circ Physiol*. 2005;**288**(5):H2140-5.
- Kurt M, Wang J, Torre-Amione G, Nagueh SF. Left atrial function in diastolic heart failure. *Circ Cardiovasc Imaging*. 2009;**2**(1):10-5.
- Mulder BJ, van der Wall EE. Size and function of the atria. *Int J Cardiovasc Imaging*. 2008;**24**(7):713-6.
- Ojaghi Haghighi Z, Naderi N, Amin A, Taghavi S, Sadeghi M, Moladoust H, et al. Quantitative assessment of right atrial function by strain and strain rate imaging in patients with heart failure. *Acta Cardiol*. 2011;**66**(6):737-42.
- Quintana M, Lindell P, Saha SK, del Furia F, Lind B, Govind S, et al. Assessment of atrial regional and global electromechanical function by tissue velocity echocardiography: a feasibility study on healthy individuals. *Cardiovasc Ultrasound*. 2005;**3**:4.
- Schneider C, Malisius R, Krause K, Lampe F, Bahlmann E, Boczor S, et al. Strain rate imaging for functional quantification of the left atrium: atrial deformation predicts the maintenance of sinus rhythm after catheter ablation of atrial fibrillation. *Eur Heart J*. 2008;**29**(11):1397-409.
- Geva T. Repaired tetralogy of Fallot: the roles of cardiovascular magnetic resonance in evaluating pathophysiology and for pulmonary valve replacement decision support. *J Cardiovasc Magn Reson*. 2011;**13**:9.
- Geva T, Gauvreau K, Powell AJ, Cecchin F, Rhodes J, Geva J, et al. Randomized trial of pulmonary valve replacement with and without right ventricular remodeling surgery. *Circulation*. 2010;**122**(11 Suppl):S201-8.
- Warnes CA, Williams RG, Bashore TM, Child JS, Connolly HM, Dearani JA, et al. ACC/AHA 2008 Guidelines for the Management of Adults with Congenital Heart Disease: a report of the American College of Cardiology/American Heart Association Task Force on Practice Guidelines (writing committee to develop guidelines on the management of adults with congenital heart disease). *Circulation*. 2008;**118**(23):e714-833.
- Rudski LG, Lai WW, Afilalo J, Hua L, Handschumacher MD, Chandrasekaran K, et al. Guidelines for the echocardiographic assessment of the right heart in adults: a report from the American Society of Echocardiography endorsed by the European Association of Echocardiography, a registered branch of the European Society of Cardiology, and the Canadian Society of Echocardiography. *J Am Soc Echocardiogr*. 2010;**23**(7):685-713.
- Hui W, Abd El Rahman MY, Dsebissowa F, Rentzsch A, Gutberlet M, Alexi-Meskishvili V, et al. Quantitative analysis of right atrial performance after surgical repair of tetralogy of Fallot. *Cardiol Young*. 2004;**14**(5):520-6.

**Please cite this paper as:** Naderi N, Ojaghi Haghighi Z, Pezeshki S, Alizadehasl A. Quantitative Assessment of Right Atrial Function by Strain Imaging in Adult Patients with Totally Corrected Tetralogy of Fallot. *Arch Cardiovasc Imaging*. 2013; **1**(1): 8-12.